



Radiosurgery Practice Guideline Initiative

Stereotactic Radiosurgery for Patients with Intracranial Arteriovenous Malformations (AVM) Radiosurgery Practice Guideline Report #2-03

Issued March 2009

**ORIGINAL GUIDELINE: September 2003
MOST RECENT LITERATURE SEARCH: March 2009**

This practice guideline, together with a report on “Intracranial Arteriovenous Malformations (AVM): Overview” is an original guideline approved by the IRSA[®] (International RadioSurgery Association) Board of Directors and issued in March 2009.

Preface

Summary

The IRSA[®] (International RadioSurgery Association) Radiosurgery Practice Guideline Initiative aims to improve outcomes for intracranial arteriovenous malformations by assisting physicians and clinicians in applying research evidence to clinical decisions while promoting the responsible use of health care resources.

Copyright

This guideline is copyrighted by IRSA (2009) and may not be reproduced without the written permission of IRSA. IRSA reserves the right to revoke copyright authorization at any time without reason.

Disclaimer

This guideline is not intended as a substitute for professional medical advice and does not address specific treatments or conditions for any patient. Those consulting this guideline are to seek qualified consultation utilizing information specific to their medical situations. Further, IRSA does not warrant any instrument or equipment nor make any representations concerning its fitness for use in any particular instance nor any other warranties whatsoever.

Key Words

- o arteriovenous malformations o AVM o vascular malformation o Gamma Knife[®]
- o stereotactic radiosurgery o linear accelerator o proton beam o irradiation
- o Bragg peak proton therapy

Consensus Statement

Objective

To develop a consensus-based radiosurgery practice guideline for treatment recommendations for brain or dural arteriovenous malformations (AVM) to be used by medical and public health professionals following the diagnosis of AVM.

Participants

The working group included physicians and physicists from the staff of major medical centers that provide radiosurgery.

Evidence

The first authors (LDL/AN) conducted a literature search in conjunction with the preparation of this document and development of other clinical guidelines. The literature identified was reviewed and opinions were sought from experts in the diagnosis and management of brain AVMs, including members of the working group.

Consensus Process

The initial draft of the consensus statement was a synthesis of research information obtained in the evidence gathering process. Members of the working group provided formal written comments that were incorporated into the preliminary draft of the statement. No significant disagreements existed. The final statement incorporates all relevant evidence obtained by the literature search in conjunction with final consensus recommendations supported by all working group members.

Group Composition

The radiosurgery guidelines group is comprised of neurosurgeons, radiation oncologists and medical physicists. Community representatives did not participate in the development of this guideline.

Names of Group Members: L. Dade Lunsford, M.D., Neurosurgeon, Chair; Douglas Kondziolka, M.D., Neurosurgeon; Ajay Niranjana, M.B.B.S., M.Ch., Neurosurgeon; Christer Lindquist, M.D., Neurosurgeon; Jay Loeffler, M.D., Radiation Oncologist; Michael McDermott, M.D., Neurosurgeon; Michael Sisti, M.D., Neurosurgeon; John C. Flickinger, M.D., Radiation Oncologist; Ann Maitz, M.S., Medical Physicist; Michael Horowitz, M.D., Neurosurgeon and Interventional Radiologist; Tonya K. Ledbetter, M.S., M.F.S., Editor; Rebecca L. Emerick, M.S., M.B.A., C.P.A., ex officio.

Conclusions

Specific recommendations are made regarding target population, treatment alternatives, interventions and practices and additional research needs. Appropriate use of radiosurgery in those with AVM following medical management may be beneficial.

This guideline is intended to provide the scientific foundation and initial framework for patients who have been diagnosed with a brain or dural arteriovenous malformation. The assessment and recommendations provided herein represent the best professional judgment of the working group at this time, based on clinical research data and expertise currently available. The conclusions and recommendations will be regularly reassessed as new information becomes available.

Stereotactic Radiosurgery

Brain Stereotactic Radiosurgery (SRS) involves the use of precisely directed, closed skull, single fraction (one session) of radiation to create a desired radiobiologic response within the brain with minimal effects to surrounding structures or tissues. In the case of an arteriovenous malformation, a relatively high dose of focused radiation is delivered precisely to the AVM under the direct supervision of a radiosurgery team. The irradiated vessels gradually occlude over a period of time. In Centers of Excellence, the radiosurgery team is composed of a neurosurgeon, radiation oncologist, physicist and registered nurse.

Intracranial Arteriovenous Malformation: Overview

Pathophysiology and Incidence

Intracranial arteriovenous malformations (AVM) constitute relatively rare and usually congenital vascular anomalies of the brain. AVMs are composed of complex connections between the arteries and veins that lack an intervening capillary bed. The arteries have a deficient muscularis layer. The draining veins often are dilated and tortuous due to the high velocity of blood flow through the fistulae. No genetic, demographic, or environmental risk factor has been associated with cerebral AVMs. Rarely inherited disorders, such as the Osler-Weber-Rendu syndrome (hereditary hemorrhagic telangiectasia), Sturge-Weber disease, neurofibromatosis, and von Hippel-Lindau syndrome are associated in a small minority of AVM patients. It is estimated that 10,000 to 12,000 new patients are diagnosed in the United States on an annual basis.

Epidemiologic Features

Sex

Both sexes are affected equally.

Age

Although AVMs are considered congenital, the clinical presentation most commonly occurs in young adults (20–40 years). Brain hemorrhage or seizure as an incident event may occur in young children or adults over 40. A history of subtle learning disorders is elicited in 66% of adults with AVMs.

Symptoms and Signs

Arteriovenous malformation patients may present with brain hemorrhage, seizures, headache or progressive neurological deficit. Many AVMs are identified because of the sudden onset of bleeding within the brain, which can be fatal or merely lead to serious headache with or without new neurological deficits. Deep-seated AVMs frequently present with hemorrhage. Hemorrhage may occur in the subarachnoid space, the intraventricular space or, most commonly, the brain parenchyma. The overall risk of intracranial hemorrhage in patients with known AVM is 2–4% per year. Specific angiographic features of the AVM increase the risk of hemorrhage. These include a small and only deep venous drainage, and relatively high arterial and venous pressures within the AVM nidus. Hemorrhage recurs in 15–20%, usually within the first year after the initial bleeding incident. Subcortical lobar AVMs may also present with seizures, progressive neurological deficits, or intractable vascular (migraine) headaches. Seizures occur as the presenting symptom in 25–50% of patients with AVM. These may be focal or secondary generalized seizures. Headache occurs in 10–50% of patients with AVM. Refractory headaches may be a presenting symptom if seizures or hemorrhages do not occur. The headache may be typical for migraine or may be present with a less specific complaint of more generalized head pain. Rarely, a progressive neurological deficit may occur over a few months to several years. The neurological deficits may be explained by the mass effect of an enlarging AVM or venous hypertension in the draining veins. In the absence of mass effect, deficit could occur due to the siphoning of blood flow away from adjacent brain tissue (the “steal phenomenon”).

Imaging Studies

Patients are identified by high resolution neurodiagnostic imaging including CT and MRI scans supplemented by complete cerebral angiography. High-quality MRI is essential for initial diagnosis of AVMs. AVMs appear as irregular or globoid masses anywhere within the hemispheres or brain stem. AVMs may be cortical, subcortical or in deep gray or white matter. Small, round, low-signal spots within or around the mass on T1, T2, or fluid-attenuated inversion recovery (FLAIR) sequences are the “flow voids” of feeding arteries, intranidal aneurysms or draining veins. If hemorrhage has occurred, the hematoma may obscure other diagnostic features, requiring angiogram or follow-up MRI. Dark signal of extracellular hemosiderin may be seen around or within the AVM mass, indicating prior hemorrhage. Aneurysms within the AVM or on feeding arteries may be identified occasionally.

Cerebral angiography is required to assess morphology and hemodynamics, which are essential for planning treatment. Important features include feeding arteries, venous drainage pattern, and arterial and venous aneurysms. Ten to fifty-eight percent of patients with AVM have aneurysms located in vessels remote from the AVM, in arteries feeding the AVM, or within the nidus of the AVM itself. Intranidal aneurysms may have a higher risk of rupture than those outside the bounds of the AVM.

Management

Once identified, arteriovenous malformations may be suitable for one or more of four management strategies: observation, surgical excision, stereotactic radiosurgery or endovascular embolization. AVM management depends on the risk of subsequent hemorrhage, which is determined by the anatomical (MRI and angiography), historical and demographic features of the individual patient. Young age, prior hemorrhage, small AVM size, deep venous drainage and high flow make subsequent hemorrhage more likely.

Observation may be most appropriate for large volume AVMs (average diameter 4–5 cm), especially for patients who have never bled. Studies of the natural history of AVMs suggest an annual hemorrhage rate of 2–4% with an annual 1% mortality rate from AVM bleeding. A second strategy is endovascular embolization, which is often used as an adjunct preceding surgical removal of the AVM via craniotomy and at times before stereotactic radiosurgery. Other vascular anomalies may be associated with AVMs, including the presence of proximal intracranial or intranidal aneurysms. Such aneurysms may pose additional risk factors to patients. Surgical management options are not part of this discussion, although incomplete surgical obliteration may prompt eventual radiosurgery. Embolization prior to radiosurgery is thought to be beneficial in some cases, but in other cases may lead to less reliable recognition of the target volume suitable for radiosurgery.⁶³ Re-canalization of embolized AVM components may require subsequent re-treatment for portions of the AVM previously thought to be occluded by successful embolization.

Stereotactic radiosurgery is considered for patients with unresectable AVMs. Such patients may warrant treatment based on age, location, volume or medical history.⁷⁷ Radiation technologies for stereotactic radiosurgery include Gamma Knife[®] radiosurgery, proton beam radiosurgery, and linear accelerators (LINACs) modified at Centers of Excellence with extensive AVM experience. Multi-modal management teams are essential for proper patient selection and patient care. Because of the delayed obliteration rate of AVMs after radiosurgery, comprehensive long-term management and observational strategies are necessary. Patients usually receive a single dose (40 mg) of methylprednisolone at the conclusion of the radiosurgery procedure. They can continue to take their other medications (antiepileptics, analgesics, etc.) after the procedure as recommended by their physicians. Postradiosurgical clinical examinations and MR studies are requested at six month intervals for the first three years to assess the effect of radiosurgery on AVM (gradual obliteration). If MRI at the three-year mark suggests complete closure of the AVM nidus, an angiogram is obtained to confirm the obliteration. If the MR imaging before three years suggests nidus obliteration, angiography is generally delayed until three full years have elapsed. If angiography after three years demonstrates that the AVM nidus is not obliterated, repeat stereotactic radiosurgery is recommended.

Dose volume guidelines for AVM management have been extensively published.^{13,17,19} AVM outcomes are best for those patients with small volume AVMs located in non-critical locations. Children may respond faster than adults in terms of the obliteration rate. Obliteration is a process resulting from endothelial proliferation within the AVM blood vessel walls, supplemented by myofibroblast proliferation. This leads to contraction and eventual obliteration of the AVM blood vessels. The process is cumulative, with earliest obliterations noted within 2–3 months, 50% of the effect often seen within one year, 80% within two years and 90% within three years. If at the end of three years residual AVM is identified by imaging, repeat radiosurgery may be considered (as may other management strategies designed to complete obliteration of the AVM).

The identification of a patient with brain or dural AVMs suitable for radiosurgery requires a commitment to long-term follow-up care and a team management strategy using the talents of neurological surgeons, radiation oncologists, neuro-imaging specialists and medical physicists. Additional management strategies include surgery, embolization, and radiosurgery alone or in combination.

Natural History of Hemorrhage Risk

The overall risk of spontaneous hemorrhage from a general brain AVM population appears to be approximately 2–4% per year.⁵⁴ In an individualized analysis of the hemorrhage risk of AVM patients prior to radiosurgery,⁵⁹ the overall crude annual hemorrhage rate was 2.40%. Multivariate analysis identified three factors associated with hemorrhage risk: history of a prior bleed, identification of a single draining vein on angiography and a diffuse AVM morphology on the angiogram.

Hemorrhage Risk After Radiosurgery but Prior to AVM Obliteration

In a study of the risk of hemorrhage during the latency interval from radiosurgery until complete AVM obliteration, the actuarial hemorrhage rate from a patent AVM (before complete obliteration) was 4.8% per year during the first two years after radiosurgery and 5.0% per year during the third to fifth years after radiosurgery.⁶⁰ Other studies also found no statistically significant departure from the natural hemorrhage rate at any time period after radiosurgical

treatment.²⁰ However, Karlsson et al., in a study of post radiosurgery hemorrhage, noted that the risk for hemorrhage decreased during the latency period.³² In addition, these authors contended that the risk for having a hemorrhage in the latency period after Gamma Knife[®] radiosurgery was dependent on the minimum dose delivered to the AVM nidus. Maruyama et al., in a retrospective analysis involving 500 patients who had undergone AVM radiosurgery, found that the risk of hemorrhage decreased by 54% during the latency period and by 88% after obliteration.⁴⁶ These authors concluded that radiosurgery may decrease the risk of hemorrhage in patients with cerebral arteriovenous malformations, even before there is angiographic evidence of obliteration. The risk of hemorrhage is further reduced, although not eliminated, after obliteration (estimated lifetime risk of a bleed is <1%).

Probability of AVM Obliteration with Radiosurgery

Current studies indicate a success rate between 50–95% at the end of three years of observation after a single radiosurgery procedure.^{1,4,5,7–10,17,21,22,33–35,38–43,47,48,51,52,56,57,61–63,66,71,74,76–79,82,84} The long-term (5–14 years) results of Gamma Knife[®] radiosurgery suggest that the majority of AVM patients (73%) are protected from the risk of future hemorrhage and continue their normal daily activities after radiosurgery.⁶³

In a study of rate of AVM obliteration after Gamma Knife[®] radiosurgery at the University of Pittsburgh, obliteration was documented by angiography in 73% and by MR alone in 86% of patients who refused further angiography.¹⁷ Assuming a 96% accuracy for MR-detected obliteration, the corrected obliteration rate for all patients was 75%.⁶⁵ Persistent out-of-field nidus (marginal failure) was identified in 18% of previously embolized versus 5% of non-embolized patients ($p = 0.006$). This was the only significant factor associated with marginal failure. Multivariate analysis correlated in-field obliteration with marginal dose ($p < 0.0001$) and sex (slightly lower in women [$p \leq 0.026$], but overall obliteration was not significantly lower [$p = 0.19$]). Ellis et al. reported out-of-field nidus in 26% of AVM patients who failed initial radiosurgery.¹²

Early Adverse Effects of Radiosurgery

Adverse effects of radiosurgery include short-term problems such as headache from the frame, nausea from pain medication, and perhaps a small increased risk of seizure in patients with cortical lobar AVMs, particularly if a prior history of episodic seizures is present.^{14,16,18,65} For this reason we use perioperative anticonvulsants in lobar AVMs.

Post-Radiosurgery Imaging Changes

The probability of developing post-radiosurgery imaging changes depends on marginal dose and treatment volume. The volume of tissue receiving 12 Gy or more (the 12-Gy volume) is the single factor that seems to have the closest correlation with the probability of developing imaging changes.²¹ Location does not seem to affect the risk of developing imaging changes but has a marked effect on whether or not these changes are associated with symptoms. Post-radiosurgery imaging changes (new areas of high T2 signal in brain surrounding the irradiated AVM nidus) develop in approximately 30% of patients 1–24 months after radiosurgery.^{14,15,18}

Two-thirds of such patients are asymptomatic, leaving approximately 9–10% of all patients to develop symptomatic post-radiosurgery imaging changes. A multi-institutional study analyzed 102 of 1255 AVM patients who developed neurological sequelae after radiosurgery.¹⁴ The median marginal dose was 19 Gy (range: 10–35 Gy) and the median treatment volume was 5.7 cc (range: 0.26–143 cc). The median follow-up after the onset of complications was 34 months (range: 9–140 months). Eighty patients had evidence of radiation related changes in the brain parenchyma. Cranial nerve deficits (7 patients), seizures (12 patients) and delayed cyst formation (5 patients) were also observed. Symptom severity was classified as minimal in 39 patients, mild in 40, disabling in 21 and fatal in 2 patients. Symptoms resolved completely in 42 of 105 patients with an actuarial complete resolution rate of 54±7% at three years post-onset.

Late Complications After AVM Radiosurgery

Delayed complications of radiosurgery on AVMs include hemorrhage despite angiographically documented complete obliteration of the AVM, temporary or permanent radiation injury to the brain such as persistent edema, radiation necrosis, radiation-induced tumors and cyst formation. Cyst formation after AVM radiosurgery was first reported by Japanese investigators who reviewed the outcomes of patients initially treated in Sweden.²⁴ Jokura et al.

recently reported a 4.7% rate of cyst formation.³⁰ Delayed cyst formation was also reported in other long-term follow-up studies.^{29,58} Patients who had delayed cyst formation were more likely to have had prior bleeds. Various surgical approaches ranging from surgical fenestration to cyst shunting were needed to manage these patients. Patients with T2 signal change without additional neurological problems generally do not need any active intervention. In a recent report Chang et al. suggested that hypofractionated stereotactic radiotherapy (HSRT) may have a lower frequency of cyst formation than SRS. However, the overall nidus obliteration rates at five years were 61% for HSRT and 81% for SRS.⁶

Of importance is the risk of radiation-induced tumors developing after radiosurgery.⁴⁴ There are reports of four malignant radiation-related tumors found 5–10 years after radiosurgery.^{25,31,70,72} It is impossible to estimate the actual incidence of radiosurgery associated cancers because the numerator (incidence) and denominator (total number of patients who underwent radiosurgery) are not available. We warn all our patients that the risk of radiation associated tumor(s) may be as high as 1 in 1000, although neither Pittsburgh experience nor the data from Sheffield, England confirm this incidence.⁶⁹

Management of Residual AVM After Radiosurgery

Repeat radiosurgery is the preferred option for most patients with residual nidus remaining three years or more after initial radiosurgery. The dose-response curve for obliterating previously treated AVM seems similar to untreated AVM. Permanent neurological sequelae were slightly higher than would be expected with no prior radiation.⁴⁵

Management of Large AVMs

Large AVMs pose a challenge for surgical resection, embolization and radiosurgery. Some may be treated using multimodal management but a population of patients with large AVMs remains “untreatable.” Although AVM embolization prior to radiosurgery has been used for patients with large AVMs, recanalization was observed in 14–15% of patients. Single-stage radiosurgery of a large volume AVM results in either unacceptable radiation-related risks due to exposure of large volumes of normal surrounding tissue or low obliteration efficacy. The obliteration rate after fractionated radiotherapy (2–4 Gy per fraction to a total dose of up to 50 Gy) is low and associated with significant side effects.³⁴ Kjellberg et al. used stereotactic Bragg peak proton beam therapy for the management of large AVMs, and found a complete obliteration rate at best in 19% of patients.³⁶ However, they postulated that some protection from further hemorrhage was achieved. In a subgroup of 48 patients with AVMs larger than 15 ml, Pan et al. found an obliteration rate of 25% after 40 months.⁵⁶ In their single radiosurgery strategy, the average margin dose was 17.7 Gy and 16.5 Gy for AVMs with volumes 10–20 ml and more than 20 ml, respectively. In their follow-up examinations, they observed 37% moderate and 12% severe adverse radiation effects in patients with AVMs larger than 10 ml. Miyawaki et al. reported that the obliteration rate in patients with AVMs larger than 14 ml treated using linear accelerator radiosurgery was 22%.⁵¹ Inoue et al. reported an obliteration rate of 36.4% and hemorrhage rate of 35.7% in the subgroup of AVMs larger than 10 ml treated by radiosurgery.²⁸ In a patient group with a mean nidus volume of 30 ml, Young et al. reported a 33.3% rate of obliteration after single radiosurgery.⁸³ It is clear that in the narrow corridor between dose response and complication, the chances of achieving a high obliteration rate with a low complication rate for large AVM radiosurgery are slim. For this reason, radiosurgical volume staging was developed as an option to manage large AVMs.⁶⁴

Staged Volume Radiosurgery

This approach is employed if the total treatment volume is expected to be more than 15 cc. Usually after outlining the total volume of the AVM nidus on the MRI, the malformation is divided into volumes (medial or lateral, superior or inferior components) using certain identified landmarks such as major vessel blood supply, the ventricles or other anatomic structures such as the internal capsule. Using the computer dose planning system, the AVM is divided into approximately equal volumes. Each stage is defined at the first procedure, and then recreated at subsequent stages using internal anatomic landmarks. The second stage radiosurgery procedure is performed 3–6 months after the first procedure. The Pittsburgh group reported an obliteration rate of 50% (7 of 14) after 36 months without new deficits, with an additional 29% showing near total obliteration.⁷⁵ Other reports have also documented the potential role of staged radiosurgery for large AVMs.⁶⁸ Longer follow-up duration is needed to assess the final outcome in these patients as some may take up to five years for nidus obliteration. The concept of volume staging with margin dose selection at a minimum of 16 Gy seems reasonably safe and effective.

Role of Preradiosurgical Embolization

Embolization may have an adjunctive role if a part of the nidus can be permanently obliterated. Preradiosurgical embolization might reduce the nidus size and/or arteriovenous shunting, which has the theoretical benefit of enhancing the efficacy of radiosurgery since a smaller volume facilitates a more effective higher dose. Beneficial effects of embolizations were reported in earlier studies.⁴⁹ Embolization and radiosurgery were performed more often in initial experience for large AVMs.¹¹ The purpose of embolizing large AVMs prior to radiosurgery is to permanently decrease the volume of the AVM and allow more effective radiosurgery. Embolization can only be an effective adjunct to radiosurgery if it results in permanent reduction of the nidus volume. Reduction in flow within the AVM does not improve radiosurgery results.

In some studies preradiosurgical embolization was a negative predictor of AVM obliteration.⁶¹ Others have reported that in 30% of patients who had their AVMs embolized, the nidus increased in size on the subsequent angiogram performed for radiosurgical targeting,⁵⁰ and 12% of embolized AVMs recanalized within a year.²³ Recanalization of embolized portions of the AVM that may have been outside the radiosurgical target results in persistent arteriovenous shunting and treatment failure. In one series, all patients with Spetzler-Martin Grade III–V AVMs who underwent incomplete embolization and subsequent radiosurgery had incomplete obliteration.⁷⁶ Unlike surgery that removes an AVM nidus within a few weeks of embolization, radiosurgery induces AVM obliteration over 2–4 years. This latency period allows sufficient time for the embolized AVM to recanalize, remodel or recruit new feeding arteries. In reported series, the combination of embolization and radiosurgery resulted in complete AVM obliteration in 47–55%, permanent neurological deficits in 5–12%, and mortality in 1.5–2.7% of patients.^{23,26,50} A recent study evaluated the obliteration rate and the clinical outcomes after radiosurgery in patients with and without previous embolization.² In this study 47 patients who had embolization and radiosurgery were compared with 47 matching patients who were treated with radiosurgery alone. Nidus obliteration was achieved in 47% of the embolization and radiosurgery group compared with 70% of the radiosurgery alone group. These data suggest that the efficacy of combined embolization and radiosurgery is either comparable or inferior to radiosurgery alone. The combination of embolization and radiosurgery does not provide any additional protection against AVM hemorrhage during the latency period, with comparable risks of hemorrhage in treated and untreated AVMs. In short, the combination of embolization and radiosurgery does not offer any advantages over radiosurgery alone and may have significant disadvantages.

Embolization is useful for patients with dural arteriovenous fistulas (DAVFs), also called dural AVMs. Dural arteriovenous fistulas involve a vascular malformation of the wall of one of the major venous sinuses or other dural structures.²⁷ The patient presentation depends on the site and overall hemodynamics of the lesion. Pulsatile tinnitus commonly occurs with lesions of the transverse or sigmoid sinus³ and may become intolerable. With cavernous sinus lesions, double vision, impaired vision and exophthalmos may occur. Superior sagittal sinus lesions can cause papilledema, vision loss and increased intracranial pressure. Cortically based lesions can lead to hemorrhages, progressive deficits or seizures. With DAVFs, the overall risk of hemorrhage is about 2% per year and depends on the site and hemodynamics of the lesion.³ The hemodynamics associated with a higher risk of hemorrhage include cortical drainage, retrograde venous drainage, presence of a venous varix, or drainage into the vein of Galen.³ Dural arteriovenous fistulas with aggressive presentation require urgent evaluation and treatment. Also, patients with intractable pulsatile tinnitus, chemosis or proptosis may be sufficiently affected by their symptoms to warrant consideration of curative or at least palliative treatment.

Treatment of DAVFs has evolved over the past three decades. In the late 1970s and 1980s, the primary treatment modality was surgical disconnection of the fistula and resection of the involved segment of dura and venous sinus.³ In the 1990s, stereotactic radiosurgery followed by transarterial particulate embolization of accessible external carotid artery feeding vessels became a primary mode of treatment at our institution. Radiosurgery results in obliteration of DAVFs between one and three years after treatment, analogous to the experience with parenchymal AVMs.^{37,53,55,67,73} Transarterial embolization, usually performed the same day and a few hours after radiosurgery, provides early palliative relief of intractable tinnitus, orbital venous congestion and symptoms such as diplopia. In addition, it substantially reduces cortical venous drainage which may reduce the risk of hemorrhage during the latent period after radiosurgery. Even if recanalization of the embolized fistula occurs, the DAVF undergoes simultaneous radiosurgery-induced obliteration. Embolization is performed after radiosurgery to avoid the pitfall of having embolization temporarily obscure portions of the nidus that would then not be targeted during the radiosurgical

procedure. Thus, the combination of radiosurgery and transarterial embolization, when possible, provides both rapid symptom relief and long-term cure of DAVFs. We prefer to perform radiosurgery first and then embolization.

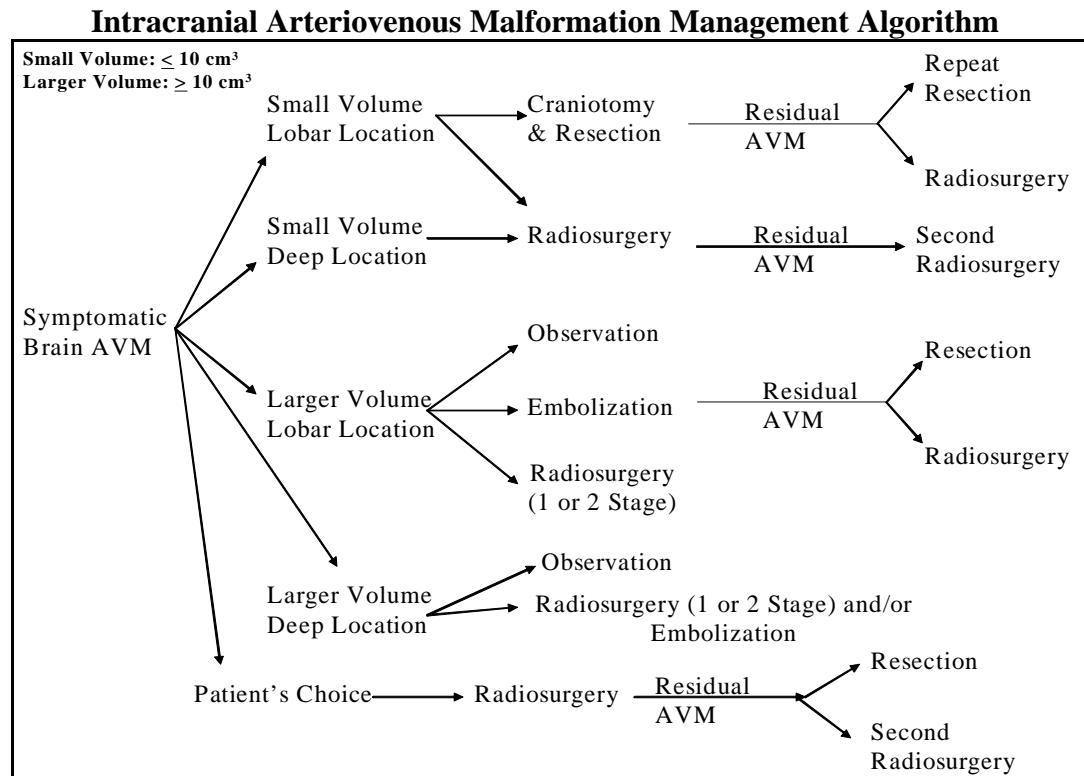
With the advent of newer materials, pre-radiosurgery embolization may have a role in the management of large AVMs in the future. Since July 2005, Onyx 18 and Onyx 34 have been approved in the United States by the Food and Drug Administration. Onyx is a nonadhesive embolic agent with lava-like flow patterns. It is possible to interrupt the injection and analyze the actual Onyx casting. For both of these reasons, it is possible to inject large volumes from one catheter position in a controlled manner and thus embolize a large part of the AVM without filling the draining veins or leptomeningeal collaterals. Due to these properties, Onyx is thought to produce permanent vascular occlusion.^{80,81}

Clinical Algorithm

A number of factors are considered in making a recommendation. These factors include:

1. Patient's age
2. Patient's medical condition
3. Previous bleed
4. Prior procedures
5. Volume of AVM
6. Location of AVM
7. Presenting symptoms

A broad outline of the management algorithm is shown below; however, the final recommendation is usually influenced by the recommending neurosurgeon's experience along with patient preference.



References

1. Altschuler EM, Lunsford LD, Coffey RJ, Bissonette DJ, Flickinger JC: Gamma knife radiosurgery for intracranial arteriovenous malformations in childhood and adolescence. **Pediatr Neurosci** **15**:53-61, 1989
2. Andrade-Souza YM, Ramani M, Scora D, Tsao MN, terBrugge K, Schwartz ML: Embolization before radiosurgery reduces the obliteration rate of arteriovenous malformations. **Neurosurgery** **60**:443-451; discussion 451-452, 2007
3. Awad IA, Little JR, Akarawi WP, Ahl J: Intracranial dural arteriovenous malformations: factors predisposing to an aggressive neurological course. **J Neurosurg** **72**:839-850, 1990
4. Betti OO, Munari C, Rosler R: Stereotactic radiosurgery with the linear accelerator: treatment of arteriovenous malformations. **Neurosurgery** **24**:311-321, 1989
5. Chang JH, Chang JW, Park YG, Chung SS: Factors related to complete occlusion of arteriovenous malformations after gamma knife radiosurgery. **J Neurosurg** **93 Suppl** **3**:96-101, 2000
6. Chang TC, Shirato H, Aoyama H, Ushikoshi S, Kato N, Kuroda S, et al: Stereotactic irradiation for intracranial arteriovenous malformation using stereotactic radiosurgery or hypofractionated stereotactic radiotherapy. **Int J Radiat Oncol Biol Phys** **60**:861-870, 2004
7. Coffey RJ, Nichols DA, Shaw EG: Stereotactic radiosurgical treatment of cerebral arteriovenous malformations. Gamma Unit Radiosurgery Study Group. **Mayo Clin Proc** **70**:214-222, 1995
8. Cohen-Gadol AA, Pollock BE: Radiosurgery for arteriovenous malformations in children. **J Neurosurg** **104**:388-391, 2006
9. Colombo F, Benedetti A, Pozza F, Marchetti C, Chierego G: Linear accelerator radiosurgery of cerebral arteriovenous malformations. **Neurosurgery** **24**:833-840, 1989
10. Colombo F, Pozza F, Chierego G, Casentini L, De Luca G, Francescon P: Linear accelerator radiosurgery of cerebral arteriovenous malformations: an update. **Neurosurgery** **34**:14-20; discussion 20-21, 1994
11. Dawson RC 3rd, Tarr RW, Hecht ST, Jungreis CA, Lunsford LD, Coffey R, et al: Treatment of arteriovenous malformations of the brain with combined embolization and stereotactic radiosurgery: results after 1 and 2 years. **AJNR Am J Neuroradiol** **11**:857-864, 1990
12. Ellis TL, Friedman WA, Bova FJ, Kubilis PS, Buatti JM: Analysis of treatment failure after radiosurgery for arteriovenous malformations. **J Neurosurg** **89**:104-110, 1998
13. Flickinger JC, Kondziolka D, Lunsford LD: Dose selection in stereotactic radiosurgery. **Neurosurg Clin N Am** **10**:271-280, 1999
14. Flickinger JC, Kondziolka D, Lunsford LD, Kassam A, Phuong LK, Liscak R, et al: Development of a model to predict permanent symptomatic postradiosurgery injury for arteriovenous malformation patients. Arteriovenous Malformation Radiosurgery Study Group. **Int J Radiat Oncol Biol Phys** **46**:1143-1148, 2000
15. Flickinger JC, Kondziolka D, Lunsford LD, Pollock BE, Yamamoto M, Gorman DA, et al: A multi-institutional analysis of complication outcomes after arteriovenous malformation radiosurgery. **Int J Radiat Oncol Biol Phys** **44**:67-74, 1999
16. Flickinger JC, Kondziolka D, Maitz AH, Lunsford LD: Analysis of neurological sequelae from radiosurgery of arteriovenous malformations: how location affects outcome. **Int J Radiat Oncol Biol Phys** **40**:273-278, 1998
17. Flickinger JC, Kondziolka D, Maitz AH, Lunsford LD: An analysis of the dose-response for arteriovenous malformation radiosurgery and other factors affecting obliteration. **Radiother Oncol** **63**:347-354, 2002
18. Flickinger JC, Kondziolka D, Pollock BE, Maitz AH, Lunsford LD: Complications from arteriovenous malformation radiosurgery: multivariate analysis and risk modeling. **Int J Radiat Oncol Biol Phys** **38**:485-490, 1997
19. Flickinger JC, Pollock BE, Kondziolka D, Lunsford LD: A dose-response analysis of arteriovenous malformation obliteration after radiosurgery. **Int J Radiat Oncol Biol Phys** **36**:873-879, 1996
20. Friedman WA, Blatt DL, Bova FJ, Buatti JM, Mendenhall WM, Kubilis PS: The risk of hemorrhage after radiosurgery for arteriovenous malformations. **J Neurosurg** **84**:912-919, 1996
21. Friedman WA, Bova FJ, Bollampally S, Bradshaw P: Analysis of factors predictive of success or complications in arteriovenous malformation radiosurgery. **Neurosurgery** **52**:296-307; discussion 307-308, 2003

22. Friedman WA, Bova FJ, Mendenhall WM: Linear accelerator radiosurgery for arteriovenous malformations: the relationship of size to outcome. **J Neurosurg** **82**:180-189, 1995
23. Gobin YP, Laurent A, Merienne L, Schlienger M, Aymard A, Houdart E, et al: Treatment of brain arteriovenous malformations by embolization and radiosurgery. **J Neurosurg** **85**:19-28, 1996
24. Hara M, Nakamura M, Shiokawa Y, Sawa H, Sato E, Koyasu H, et al: Delayed cyst formation after radiosurgery for cerebral arteriovenous malformation: two case reports. **Minim Invasive Neurosurg** **41**:40-45, 1998
25. Heikkinen ER, Konnov B, Melnikov L, Yalynych N, Zubkov Yu N, Garmashov Yu A, et al: Relief of epilepsy by radiosurgery of cerebral arteriovenous malformations. **Stereotact Funct Neurosurg** **53**:157-166, 1989
26. Henkes H, Nahser HC, Berg-Dammer E, Weber W, Lange S, Kuhne D: Endovascular therapy of brain AVMs prior to radiosurgery. **Neurol Res** **20**:479-492, 1998
27. Houser OW, Campbell JK, Campbell RJ, Sundt TM, Jr.: Arteriovenous malformation affecting the transverse dural venous sinus--an acquired lesion. **Mayo Clin Proc** **54**:651-661, 1979
28. Inoue HK, Ohye C: Hemorrhage risks and obliteration rates of arteriovenous malformations after gamma knife radiosurgery. **J Neurosurg** **97**:474-476, 2002
29. Izawa M, Hayashi M, Chernov M, Nakaya K, Ochiai T, Murata N, et al: Long-term complications after gamma knife surgery for arteriovenous malformations. **J Neurosurg** **102 Suppl**:34-37, 2005
30. Jokura H, Kawagishi J, Sugai K, Akabane A, Boku N, Takahashi K: Gamma knife radiosurgery for arteriovenous malformations: the Furukawa experience. **Prog Neurol Surg** **22**:20-30, 2009
31. Kaido T, Hoshida T, Uranishi R, Akita N, Kotani A, Nishi N, et al: Radiosurgery-induced brain tumor. Case report. **J Neurosurg** **95**:710-713, 2001
32. Karlsson B, Lax I, Soderman M: Risk for hemorrhage during the 2-year latency period following gamma knife radiosurgery for arteriovenous malformations. **Int J Radiat Oncol Biol Phys** **49**:1045-1051, 2001
33. Karlsson B, Lindquist C, Steiner L: Prediction of obliteration after gamma knife surgery for cerebral arteriovenous malformations. **Neurosurgery** **40**:425-430; discussion 430-431, 1997
34. Karlsson B, Lindqvist M, Blomgren H, Wan-Yeo G, Soderman M, Lax I, et al: Long-term results after fractionated radiation therapy for large brain arteriovenous malformations. **Neurosurgery** **57**:42-49; discussion 42-49, 2005
35. Kida Y: [Radiosurgery for intracranial dural arteriovenous fistulas--indications for limitations for gamma knife treatment]. **Brain Nerve** **60**:915-921, 2008
36. Kjellberg RN, Hanamura T, Davis KR, Lyons SL, Adams RD: Bragg-peak proton-beam therapy for arteriovenous malformations of the brain. **N Engl J Med** **309**:269-274, 1983
37. Koebbe CJ, Singhal D, Sheehan J, Flickinger JC, Horowitz M, Kondziolka D, et al: Radiosurgery for dural arteriovenous fistulas. **Surg Neurol** **64**:392-398; discussion 398-399, 2005
38. Kwon Y, Jeon SR, Kim JH, Lee JK, Ra DS, Lee DJ, et al: Analysis of the causes of treatment failure in gamma knife radiosurgery for intracranial arteriovenous malformations. **J Neurosurg** **93 Suppl 3**:104-106, 2000
39. Lax I, Karlsson B: Prediction of complications in gamma knife radiosurgery of arteriovenous malformation. **Acta Oncol** **35**:49-55, 1996
40. Levy EI, Niranjan A, Thompson TP, Scarrow AM, Kondziolka D, Flickinger JC, et al: Radiosurgery for childhood intracranial arteriovenous malformations. **Neurosurgery** **47**:834-841; discussion 841-842, 2000
41. Lindqvist M, Karlsson B, Guo WY, Kihlstrom L, Lippitz B, Yamamoto M: Angiographic long-term follow-up data for arteriovenous malformations previously proven to be obliterated after gamma knife radiosurgery. **Neurosurgery** **46**:803-808; discussion 809-810, 2000
42. Liscak R, Vladyka V, Simonova G, Urgosik D, Novotny J, Jr., Janouskova L, et al: Arteriovenous malformations after Leksell gamma knife radiosurgery: rate of obliteration and complications. **Neurosurgery** **60**:1005-1014; discussion 1015-1016, 2007
43. Loeffler JS, Alexander E 3rd, Siddon RL, Saunders WM, Coleman CN, Winston KR: Stereotactic radiosurgery for intracranial arteriovenous malformations using a standard linear accelerator. **Int J Radiat Oncol Biol Phys** **17**:673-677, 1989
44. Loeffler JS, Niemierko A, Chapman PH: Second tumors after radiosurgery: tip of the iceberg or a bump in the road? **Neurosurgery** **52**:1436-1440; discussion 1440-1442, 2003
45. Maesawa S, Flickinger JC, Kondziolka D, Lunsford LD: Repeated radiosurgery for incompletely obliterated arteriovenous malformations. **J Neurosurg** **92**:961-970, 2000

46. Maruyama K, Kawahara N, Shin M, Tago M, Kishimoto J, Kurita H, et al: The risk of hemorrhage after radiosurgery for cerebral arteriovenous malformations. **N Engl J Med** **352**:146-153, 2005
47. Maruyama K, Kondziolka D, Niranjan A, Flickinger JC, Lunsford LD: Stereotactic radiosurgery for brainstem arteriovenous malformations: factors affecting outcome. **J Neurosurg** **100**:407-413, 2004
48. Maruyama K, Shin M, Tago M, Kurita H, Kawamoto S, Morita A, et al: Gamma knife surgery for arteriovenous malformations involving the corpus callosum. **J Neurosurg** **102 Suppl**:49-52, 2005
49. Mathis JA, Barr JD, Horton JA, Jungreis CA, Lunsford LD, Kondziolka DS, et al: The efficacy of particulate embolization combined with stereotactic radiosurgery for treatment of large arteriovenous malformations of the brain. **AJNR Am J Neuroradiol** **16**:299-306, 1995
50. Miyachi S, Negoro M, Okamoto T, Kobayashi T, Kida Y, Tanaka T, et al: Embolisation of cerebral arteriovenous malformations to assure successful subsequent radiosurgery. **J Clin Neurosci** **7 Suppl** **1**:82-85, 2000
51. Miyawaki L, Dowd C, Wara W, Goldsmith B, Albright N, Gutin P, et al: Five year results of LINAC radiosurgery for arteriovenous malformations: outcome for large AVMS. **Int J Radiat Oncol Biol Phys** **44**:1089-1106, 1999
52. Nicolato A, Gerosa M, Ferraresi P, Piovan E, Pasoli A, Perini S, et al: Stereotactic radiosurgery for the treatment of arteriovenous malformations in childhood. **J Neurosurg Sci** **41**:359-371, 1997
53. O'Leary S, Hodgson TJ, Coley SC, Kemeny AA, Radatz MW: Intracranial dural arteriovenous malformations: results of stereotactic radiosurgery in 17 patients. **Clin Oncol (R Coll Radiol)** **14**:97-102, 2002
54. Ondra SL, Troupp H, George ED, Schwab K: The natural history of symptomatic arteriovenous malformations of the brain: a 24-year follow-up assessment. **J Neurosurg** **73**:387-391, 1990
55. Pan DH, Chung WY, Guo WY, Wu HM, Liu KD, Shiau CY, et al: Stereotactic radiosurgery for the treatment of dural arteriovenous fistulas involving the transverse-sigmoid sinus. **J Neurosurg** **96**:823-829, 2002
56. Pan DH, Guo WY, Chung WY, Shiau CY, Chang YC, Wang LW: Gamma knife radiosurgery as a single treatment modality for large cerebral arteriovenous malformations. **J Neurosurg** **93 Suppl** **3**:113-119, 2000
57. Pan DH, Kuo YH, Guo WY, Chung WY, Wu HM, Liu KD, et al: Gamma Knife surgery for cerebral arteriovenous malformations in children: a 13-year experience. **J Neurosurg Pediatrics** **1**:296-304, 2008
58. Pan HC, Sheehan J, Stroila M, Steiner M, Steiner L: Late cyst formation following gamma knife surgery of arteriovenous malformations. **J Neurosurg** **102 Suppl**:124-127, 2005
59. Pollock BE, Flickinger JC, Lunsford LD, Bissonette DJ, Kondziolka D: Factors that predict the bleeding risk of cerebral arteriovenous malformations. **Stroke** **27**:1-6, 1996
60. Pollock BE, Flickinger JC, Lunsford LD, Bissonette DJ, Kondziolka D: Hemorrhage risk after stereotactic radiosurgery of cerebral arteriovenous malformations. **Neurosurgery** **38**:652-659; discussion 659-661, 1996
61. Pollock BE, Flickinger JC, Lunsford LD, Maitz A, Kondziolka D: Factors associated with successful arteriovenous malformation radiosurgery. **Neurosurgery** **42**:1239-1244; discussion 1244-1247, 1998
62. Pollock BE, Gorman DA, Brown PD: Radiosurgery for arteriovenous malformations of the basal ganglia, thalamus, and brainstem. **J Neurosurg** **100**:210-214, 2004
63. Pollock BE, Gorman DA, Coffey RJ: Patient outcomes after arteriovenous malformation radiosurgical management: results based on a 5- to 14-year follow-up study. **Neurosurgery** **52**:1291-1296; discussion 1296-1297, 2003
64. Pollock BE, Kline RW, Stafford SL, Foote RL, Schomberg PJ: The rationale and technique of staged-volume arteriovenous malformation radiosurgery. **Int J Radiat Oncol Biol Phys** **48**:817-824, 2000
65. Pollock BE, Kondziolka D, Flickinger JC, Patel AK, Bissonette DJ, Lunsford LD: Magnetic resonance imaging: an accurate method to evaluate arteriovenous malformations after stereotactic radiosurgery. **J Neurosurg** **85**:1044-1049, 1996
66. Pollock BE, Lunsford LD, Kondziolka D, Maitz A, Flickinger JC: Patient outcomes after stereotactic radiosurgery for "operable" arteriovenous malformations. **Neurosurgery** **35**:1-7; discussion 7-8, 1994
67. Pollock BE, Nichols DA, Garrity JA, Gorman DA, Stafford SL: Stereotactic radiosurgery and particulate embolization for cavernous sinus dural arteriovenous fistulae. **Neurosurgery** **45**:459-466; discussion 466-467, 1999

68. Raza SM, Jabbour S, Thai QA, Pradilla G, Kleinberg LR, Wharam M, et al: Repeat stereotactic radiosurgery for high-grade and large intracranial arteriovenous malformations. **Surg Neurol** **68**:24-34; discussion 34, 2007
69. Rowe J, Grainger A, Walton L, Silcocks P, Radatz M, Kemeny A: Risk of malignancy after gamma knife stereotactic radiosurgery. **Neurosurgery** **60**:60-65; discussion 65-66, 2007
70. Sanno N, Hayashi S, Shimura T, Maeda S, Teramoto A: Intracranial osteosarcoma after radiosurgery--case report. **Neurol Med Chir (Tokyo)** **44**:29-32, 2004
71. Schlienger M, Atlan D, Lefkopoulos D, Merienne L, Touboul E, Missir O, et al: Linac radiosurgery for cerebral arteriovenous malformations: results in 169 patients. **Int J Radiat Oncol Biol Phys** **46**:1135-1142, 2000
72. Shamisa A, Bance M, Nag S, Tator C, Wong S, Noren G, et al: Glioblastoma multiforme occurring in a patient treated with gamma knife surgery. Case report and review of the literature. **J Neurosurg** **94**:816-821, 2001
73. Shin M, Kurita H, Tago M, Kirino T: Stereotactic radiosurgery for tentorial dural arteriovenous fistulae draining into the vein of Galen: report of two cases. **Neurosurgery** **46**:730-733; discussion 733-734, 2000
74. Shin M, Maruyama K, Kurita H, Kawamoto S, Tago M, Terahara A, et al: Analysis of nidus obliteration rates after gamma knife surgery for arteriovenous malformations based on long-term follow-up data: the University of Tokyo experience. **J Neurosurg** **101**:18-24, 2004
75. Sirin S, Kondziolka D, Niranjan A, Flickinger JC, Maitz AH, Lunsford LD: Prospective staged volume radiosurgery for large arteriovenous malformations: indications and outcomes in otherwise untreatable patients. **Neurosurgery** **62 Suppl 2**:744-754, 2008
76. Smith KA, Shetter A, Speiser B, Spetzler RF: Angiographic follow-up in 37 patients after radiosurgery for cerebral arteriovenous malformations as part of a multimodality treatment approach. **Stereotact Funct Neurosurg** **69**:136-142, 1997
77. Starke RM, Komotar RJ, Hwang BY, Fischer LE, Otten ML, Merkow MB, et al: A comprehensive review of radiosurgery for cerebral arteriovenous malformations: outcomes, predictive factors, and grading scales. **Stereotact Funct Neurosurg** **86**:191-199, 2008
78. Steiner L, Leksell L, Forster DM, Greitz T, Backlund EO: Stereotactic radiosurgery in intracranial arteriovenous malformations. **Acta Neurochir (Wien) Suppl** **21**:195-209, 1974
79. Steiner L, Lindquist C, Adler JR, Torner JC, Alves W, Steiner M: Outcome of radiosurgery for cerebral AVM. **J Neurosurg** **77**:823, 1992
80. van Rooij WJ, Sluzewski M, Beute GN: Brain AVM embolization with Onyx. **AJNR Am J Neuroradiol** **28**:172-177; discussion 178, 2007
81. Weber W, Kis B, Siekmann R, Kuehne D: Endovascular treatment of intracranial arteriovenous malformations with onyx: technical aspects. **AJNR Am J Neuroradiol** **28**:371-377, 2007
82. Yamamoto M, Jimbo M, Kobayashi M, Toyoda C, Ide M, Tanaka N, et al: Long-term results of radiosurgery for arteriovenous malformation: neurodiagnostic imaging and histological studies of angiographically confirmed nidus obliteration. **Surg Neurol** **37**:219-230, 1992
83. Yang SY, Kim DG, Chung HT, Paek SH, Park JH, Han DH: Radiosurgery for large cerebral arteriovenous malformations. **Acta Neurochir (Wien)** **151**:113-124, 2009
84. Zabel-du Bois A, Milker-Zabel S, Huber P, Schlegel W, Debus J: Pediatric cerebral arteriovenous malformations: the role of stereotactic linac-based radiosurgery. **Int J Radiat Oncol Biol Phys** **65**:1206-1211, 2006

COMPLETE SUMMARY

GUIDELINE TITLE

Stereotactic radiosurgery for patients with intracranial arteriovenous malformations (AVM).

BIBLIOGRAPHIC SOURCE

International RadioSurgery Association (IRSA). Stereotactic radiosurgery for patients with intracranial arteriovenous malformations (AVM). Harrisburg (PA): International RadioSurgery Association (IRSA); 2009 March. 22 p. (Radiosurgery practice guideline report; no. 2-03). [84 references]

GUIDELINE STATUS

This is the updated release of the guideline.

DISEASE/CONDITION

Arteriovenous malformations of the brain or dura

GUIDELINE CATEGORY

Evaluation
Management
Treatment

CLINICAL SPECIALTY

Neurological surgery
Neurology
Radiation oncology

INTENDED USERS

Advanced Practice Nurses
Allied Health Personnel
Health Care Providers
Hospitals
Managed Care Organizations
Nurses
Patients
Physicians
Utilization Management

GUIDELINE OBJECTIVES

- To develop an evidence and consensus-based radiosurgery practice guideline for treatment recommendations for brain or dural arteriovenous malformations to be used by medical and public health professionals following the diagnosis of AVM.
- To improve outcomes for AVM radiosurgery by assisting physicians and clinicians in applying research evidence to clinical decisions while promoting the responsible use of health care resources.

TARGET POPULATION

Patients with imaging identified arteriovenous malformation(s).

INTERVENTIONS AND PRACTICES CONSIDERED

1. Stereotactic radiosurgery
 - Intraoperative stereotactic guidance
 - Digitally acquired images (computed tomography [CT] or magnetic resonance imaging [MRI])
 - Intracranial angiography

2. Methylprednisolone treatment

MAJOR OUTCOMES CONSIDERED

- Total obliteration of the arteriovenous malformation within three years is the primary end point of interest
- Resolution or improvement in seizure disorders if present
- Resolution or reduction in vascular headache syndromes
- Prevention of bleeding risks from the arteriovenous malformation (estimated to vary between 1–10% per year depending upon prior bleeding history, location, and volume)
- Improvement in existing neurological deficits
- Maintenance of quality of life and employability
- Prevention of adverse radiation effects

METHODS USED TO COLLECT/SELECT EVIDENCE

Hand-searches of Published Literature (Primary Sources)
Hand-searches of Published Literature (Secondary Sources)
Searches of Electronic Databases
Clinical Experience

DESCRIPTION OF METHODS USED TO COLLECT/SELECT THE EVIDENCE

MEDLINE and PUBMED searches were completed for the years 1966 to March 2009. Search terms included: arteriovenous malformation, vascular malformation, stereotactic radiosurgery, Gamma Knife[®], irradiation, linear accelerator, clinical trials, research design, practice guidelines and meta-analysis. Bibliographies from recent published reviews were reviewed and relevant articles were retrieved.

NUMBER OF SOURCE DOCUMENTS

84

METHODS USED TO ASSESS THE QUALITY AND STRENGTH OF THE EVIDENCE

Expert consensus (committee)
Weighting according to a rating scheme (scheme given)

RATING SCHEME FOR THE STRENGTH OF THE EVIDENCE

This classification is based on the Bandolier system (<http://www.medicine.ox.ac.uk/bandolier/band6/b6-5.html>) adapted for a systematic review.

Type & Strength of Evidence in Medical Literature

Type I: Evidence from a systematic review (which includes at least one randomized controlled trial and a summary of all included studies).

Type II: Evidence from a well designed randomized controlled trial of appropriate size.

Type III: Evidence from a well designed intervention study without randomization. A common research design is the before-and-after study.

Type IV: Evidence from a well designed non-experimental study, e.g., cohort, case-control or cross-sectional studies. (Also includes studies using purely qualitative methods. Economic analyses [cost-effectiveness studies] are also classified as Type IV evidence.)

Type V: Opinions of respected authorities, based on clinical evidence, descriptive studies or reports of expert consensus committees.

METHODS USED TO ANALYZE THE EVIDENCE

Review of published meta-analyses
Systematic review with evidence tables

DESCRIPTION OF THE METHODS USED TO ANALYZE THE EVIDENCE

The literature identified was reviewed and opinions were sought from experts in the diagnosis and management of AVMs, including members of the working group.

METHODS USED TO FORMULATE THE RECOMMENDATIONS

Expert consensus

DESCRIPTION OF METHODS USED TO FORMULATE THE RECOMMENDATIONS

The working group included physicians and physicists from the staff of major medical centers that provide radiosurgery. The initial draft of the consensus statement was a synthesis of research information obtained in the evidence gathering process.

Members of the working group provided formal written comments that were incorporated into the preliminary draft of the statement. No significant disagreements existed.

The final statement incorporates all relevant evidence obtained by the literature search in conjunction with the final consensus recommendations supported by all working group members listed in the original guideline document.

RATING SCHEME FOR THE STRENGTH OF THE RECOMMENDATIONS

Not applicable

COST ANALYSIS

Guideline developers reviewed published cost analyses.

METHOD OF GUIDELINE VALIDATION

External Peer Review
Internal Peer Review

DESCRIPTION OF METHOD OF GUIDELINE VALIDATION

The recommendations were e-mailed to all committee members. Feedback was obtained through this e-mail survey consisting of proposed guidelines asking for comments on the guidelines and whether the recommendation should serve as a practice guideline. No significant disagreements existed.

This practice guideline, together with a report on “Intracranial Arteriovenous Malformations (AVM): Overview” is an updated guideline approved by the International RadioSurgery Association and issued in March 2009.

MAJOR RECOMMENDATIONS:

Stereotactic radiosurgery is defined as a relatively high dose of focused radiation delivered precisely to the arteriovenous malformations, under the direct supervision of a medical team (neurosurgeon, radiation oncologist, registered nurse, and medical physicist), in one surgical session.

Patient Selection

- Patients with intracranial AVM defined by modern neurodiagnostic imaging, including CT, MRI and cerebral angiography, should be considered for radiosurgery. Such patients typically present with brain hemorrhage (especially when located in deep anatomic locations of the brain), persistent seizures, vascular headache syndrome or progressive neurological deficits.
- The selection of patients suitable for radiosurgery is dependent on prior bleeding history, age of the patient, existing co-morbidities, anatomic location and clinical history.

Treatment/Management

- Arteriovenous malformations are considered suitable for four management strategies alone or in combination: observation only, surgical excision, endovascular embolization (designed to reduce either a selected volume or flow through the AVM), and stereotactic radiosurgery.
- Stereotactic radiosurgery is typically employed alone but may also be employed in combination with prior surgery or embolization in particular circumstances. Size ranges of average diameter are usually less than 3 cm (0.1–10 cm³). Prospective stereotactic radiosurgery volumetric staging is frequently performed for those symptomatic patients with AVM volumes >15 cm³ in the absence of other acceptable risk management strategies and can be considered for AVMs 10–15 cm³ in volume.
- The optimal dose range for volumetric conformal stereotactic AVM radiosurgery has been largely established based on location and volume of the AVM. Doses at the margin of the AVM typically range from 16–25 Gy in a single fraction, wherein the volume of the AVM is defined by stereotactic guidance during the procedure itself. Stereotactic volumetric axial plane imaging (MRI or CT) supplemented by conventional or digital subtraction angiography is usually necessary for complete conformal dose planning.
- Dose selection depends on location, volume, estimated adverse radiation risks, pre-existing neurological conditions and prior bleeding history. Depending upon the technology used, the margin of the AVM dose is usually 50–70% of the central target dose within the AVM. Sharp fall-off of the radiation dose outside of the target volume is required. Current radiation delivery technologies for volumetric stereotactic conformal single fraction radiosurgery include Gamma Knife[®], proton beam using Bragg peak effect, and specially modified linear accelerators.
- Patients usually receive a single dose (40 mg) of methylprednisolone at the conclusion of the radiosurgery procedure. They can continue to take their other medications (e.g., antiepileptics, analgesics) during and after the procedure as recommended by their physicians.
- Some AVM patients will have been previously treated by embolization for volumetric reduction or flow reduction. Some patients may have had prior intracranial surgery for blood clot (hematoma) evacuation or partial AVM resection. The safe interval between surgery and stereotactic radiosurgery is not known, but it is reasonable to perform radiosurgery once the patient has achieved a stable neurological recovery or plateau (generally within two to three months after the intracranial hemorrhage or prior surgery). The optimal time between prior embolization and radiosurgery is not known, but generally waiting for a period of several weeks is considered beneficial in order to reduce the likelihood of vascular ischemic complications or residual cerebral edema sometimes associated with embolization followed by early radiosurgery.
- Postradiosurgical clinical examinations and MR studies are requested by referring physicians at six-month intervals for the first three years to assess the effect of radiosurgery on AVM (gradual obliteration). If MR at the three-year mark suggests complete disappearance of the AVM nidus, an angiogram is obtained to confirm the obliteration. If the MR imaging before three years suggests nidus obliteration, angiography is generally delayed until three full years have elapsed. If angiography after three years demonstrates that the AVM nidus is not obliterated, repeat stereotactic radiosurgery is recommended.
- Patients who have residual arteriovenous malformations identified by neurodiagnostic imaging at three years (after radiosurgery) may be candidates for a second stereotactic radiosurgical

procedure. Alternatively, patients with larger volume AVMs (>10 cm³) may be considered suitable for up-front volumetric staging of AVMs by treating different anatomic components of the AVM at intervals staged between three and six months. The interval for staging of radiosurgery prospectively is not established. Stereotactic radiosurgery should not be considered as the panacea for large volume AVMs unsuitable for surgery or embolization. At selected centers with experience, estimated obliteration rates at five years after two radiosurgical procedures approach 60–70%. For smaller volume AVMs (average diameters <3 cm³), estimated complete obliteration rates at three years after a single procedure vary from 70–90%.

- Causes for failure of stereotactic radiosurgery have been identified and include inadequate visualization of the target nidus, lack of intraoperative stereotactic 3-D (volumetric axial plane imaging), insufficient dose to achieve the obliterative response, compression of the AVM nidus by a prior hematoma, or poor nidus visualization secondary to overlying vascular structures. In a few cases, selected radiobiological resistance of undetermined etiology may be the cause of obliteration failure.
- At present, technologies designed to provide volumetric stereotactic radiosurgery are limited to Gamma Knife[®], modified linear accelerators at centers supplemented by significant experience, and proton beam facilities in the United States.

CLINICAL ALGORITHM

The original guideline contains a clinical algorithm for arteriovenous malformation management.

REFERENCES SUPPORTING THE MAJOR RECOMMENDATIONS

1. Altschuler EM, Lunsford LD, Coffey RJ, Bissonette DJ, Flickinger JC: Gamma knife radiosurgery for intracranial arteriovenous malformations in childhood and adolescence. **Pediatr Neurosci** 15:53-61, 1989
2. Chang JH, Chang JW, Park YG, Chung SS: Factors related to complete occlusion of arteriovenous malformations after gamma knife radiosurgery. **J Neurosurg** 93 Suppl 3:96-101, 2000
3. Coffey RJ, Nichols DA, Shaw EG: Stereotactic radiosurgical treatment of cerebral arteriovenous malformations. Gamma Unit Radiosurgery Study Group. **Mayo Clin Proc** 70:214-222, 1995
4. Cohen-Gadol AA, Pollock BE: Radiosurgery for arteriovenous malformations in children. **J Neurosurg** 104:388-391, 2006
5. Colombo F, Benedetti A, Pozza F, Marchetti C, Chierago G: Linear accelerator radiosurgery of cerebral arteriovenous malformations. **Neurosurgery** 24:833-840, 1989
6. Colombo F, Pozza F, Chierago G, Casentini L, De Luca G, Francescon P: Linear accelerator radiosurgery of cerebral arteriovenous malformations: an update. **Neurosurgery** 34:14-20; discussion 20-21, 1994
7. Dawson RC 3rd, Tarr RW, Hecht ST, Jungreis CA, Lunsford LD, Coffey R, et al: Treatment of arteriovenous malformations of the brain with combined embolization and stereotactic radiosurgery: results after 1 and 2 years. **AJNR Am J Neuroradiol** 11:857-864, 1990
8. Ellis TL, Friedman WA, Bova FJ, Kubilis PS, Buatti JM: Analysis of treatment failure after radiosurgery for arteriovenous malformations. **J Neurosurg** 89:104-110, 1998
9. Flickinger JC, Kondziolka D, Lunsford LD: Dose selection in stereotactic radiosurgery. **Neurosurg Clin N Am** 10:271-280, 1999
10. Flickinger JC, Kondziolka D, Lunsford LD, Kassam A, Phuong LK, Liscak R, et al: Development of a model to predict permanent symptomatic postradiosurgery injury for arteriovenous malformation patients. Arteriovenous Malformation Radiosurgery Study Group. **Int J Radiat Oncol Biol Phys** 46:1143-1148, 2000
11. Flickinger JC, Kondziolka D, Lunsford LD, Pollock BE, Yamamoto M, Gorman DA, et al: A multi-institutional analysis of complication outcomes after arteriovenous malformation radiosurgery. **Int J Radiat Oncol Biol Phys** 44:67-74, 1999
12. Flickinger JC, Kondziolka D, Maitz AH, Lunsford LD: Analysis of neurological sequelae from radiosurgery of arteriovenous malformations: how location affects outcome. **Int J Radiat Oncol Biol Phys** 40:273-278, 1998

13. Flickinger JC, Kondziolka D, Maitz AH, Lunsford LD: An analysis of the dose-response for arteriovenous malformation radiosurgery and other factors affecting obliteration. **Radiother Oncol** **63**:347-354, 2002
14. Flickinger JC, Kondziolka D, Pollock BE, Maitz AH, Lunsford LD: Complications from arteriovenous malformation radiosurgery: multivariate analysis and risk modeling. **Int J Radiat Oncol Biol Phys** **38**:485-490, 1997
15. Flickinger JC, Pollock BE, Kondziolka D, Lunsford LD: A dose-response analysis of arteriovenous malformation obliteration after radiosurgery. **Int J Radiat Oncol Biol Phys** **36**:873-879, 1996
16. Friedman WA, Blatt DL, Bova FJ, Buatti JM, Mendenhall WM, Kubilis PS: The risk of hemorrhage after radiosurgery for arteriovenous malformations. **J Neurosurg** **84**:912-919, 1996
17. Friedman WA, Bova FJ, Bollampally S, Bradshaw P: Analysis of factors predictive of success or complications in arteriovenous malformation radiosurgery. **Neurosurgery** **52**:296-307; discussion 307-308, 2003
18. Inoue HK, Ohye C: Hemorrhage risks and obliteration rates of arteriovenous malformations after gamma knife radiosurgery. **J Neurosurg** **97**:474-476, 2002
19. Izawa M, Hayashi M, Chernov M, Nakaya K, Ochiai T, Murata N, et al: Long-term complications after gamma knife surgery for arteriovenous malformations. **J Neurosurg** **102 Suppl**:34-37, 2005
20. Kaido T, Hoshida T, Uranishi R, Akita N, Kotani A, Nishi N, et al: Radiosurgery-induced brain tumor. Case report. **J Neurosurg** **95**:710-713, 2001
22. Karlsson B, Lax I, Soderman M: Risk for hemorrhage during the 2-year latency period following gamma knife radiosurgery for arteriovenous malformations. **Int J Radiat Oncol Biol Phys** **49**:1045-1051, 2001
23. Karlsson B, Lindquist C, Steiner L: Prediction of obliteration after gamma knife surgery for cerebral arteriovenous malformations. **Neurosurgery** **40**:425-430; discussion 430-431, 1997
24. Kjellberg RN, Hanamura T, Davis KR, Lyons SL, Adams RD: Bragg-peak proton-beam therapy for arteriovenous malformations of the brain. **N Engl J Med** **309**:269-274, 1983
25. Koebbe CJ, Singhal D, Sheehan J, Flickinger JC, Horowitz M, Kondziolka D, et al: Radiosurgery for dural arteriovenous fistulas. **Surg Neurol** **64**:392-398; discussion 398-399, 2005
26. Levy EI, Niranjan A, Thompson TP, Scarrow AM, Kondziolka D, Flickinger JC, et al: Radiosurgery for childhood intracranial arteriovenous malformations. **Neurosurgery** **47**:834-841; discussion 841-842, 2000
27. Lindqvist M, Karlsson B, Guo WY, Kihlstrom L, Lippitz B, Yamamoto M: Angiographic long-term follow-up data for arteriovenous malformations previously proven to be obliterated after gamma knife radiosurgery. **Neurosurgery** **46**:803-808; discussion 809-810, 2000
28. Liscak R, Vladyka V, Simonova G, Urgosik D, Novotny J, Jr., Janouskova L, et al: Arteriovenous malformations after Leksell gamma knife radiosurgery: rate of obliteration and complications. **Neurosurgery** **60**:1005-1014; discussion 1015-1016, 2007
29. Loeffler JS, Alexander E 3rd, Siddon RL, Saunders WM, Coleman CN, Winston KR: Stereotactic radiosurgery for intracranial arteriovenous malformations using a standard linear accelerator. **Int J Radiat Oncol Biol Phys** **17**:673-677, 1989
30. Maesawa S, Flickinger JC, Kondziolka D, Lunsford LD: Repeated radiosurgery for incompletely obliterated arteriovenous malformations. **J Neurosurg** **92**:961-970, 2000
31. Maruyama K, Kawahara N, Shin M, Tago M, Kishimoto J, Kurita H, et al: The risk of hemorrhage after radiosurgery for cerebral arteriovenous malformations. **N Engl J Med** **352**:146-153, 2005
32. Maruyama K, Kondziolka D, Niranjan A, Flickinger JC, Lunsford LD: Stereotactic radiosurgery for brainstem arteriovenous malformations: factors affecting outcome. **J Neurosurg** **100**:407-413, 2004
33. Pan DH, Guo WY, Chung WY, Shiao CY, Chang YC, Wang LW: Gamma knife radiosurgery as a single treatment modality for large cerebral arteriovenous malformations. **J Neurosurg** **93 Suppl** **3**:113-119, 2000
34. Pan DH, Kuo YH, Guo WY, Chung WY, Wu HM, Liu KD, et al: Gamma Knife surgery for cerebral arteriovenous malformations in children: a 13-year experience. **J Neurosurg Pediatrics** **1**:296-304, 2008
35. Pollock BE, Flickinger JC, Lunsford LD, Bissonette DJ, Kondziolka D: Factors that predict the bleeding risk of cerebral arteriovenous malformations. **Stroke** **27**:1-6, 1996

36. Pollock BE, Flickinger JC, Lunsford LD, Bissonette DJ, Kondziolka D: Hemorrhage risk after stereotactic radiosurgery of cerebral arteriovenous malformations. **Neurosurgery** **38**:652-659; discussion 659-661, 1996
37. Pollock BE, Gorman DA, Coffey RJ: Patient outcomes after arteriovenous malformation radiosurgical management: results based on a 5- to 14-year follow-up study. **Neurosurgery** **52**:1291-1296; discussion 1296-1297, 2003
38. Pollock BE, Kline RW, Stafford SL, Foote RL, Schomberg PJ: The rationale and technique of staged-volume arteriovenous malformation radiosurgery. **Int J Radiat Oncol Biol Phys** **48**:817-824, 2000
39. Pollock BE, Nichols DA, Garrity JA, Gorman DA, Stafford SL: Stereotactic radiosurgery and particulate embolization for cavernous sinus dural arteriovenous fistulae. **Neurosurgery** **45**:459-466; discussion 466-467, 1999
40. Shin M, Maruyama K, Kurita H, Kawamoto S, Tago M, Terahara A, et al: Analysis of nidus obliteration rates after gamma knife surgery for arteriovenous malformations based on long-term follow-up data: the University of Tokyo experience. **J Neurosurg** **101**:18-24, 2004
41. Sirin S, Kondziolka D, Niranjan A, Flickinger JC, Maitz AH, Lunsford LD: Prospective staged volume radiosurgery for large arteriovenous malformations: indications and outcomes in otherwise untreatable patients. **Neurosurgery** **62 Suppl 2**:744-754, 2008
42. Steiner L, Leksell L, Forster DM, Greitz T, Backlund EO: Stereotactic radiosurgery in intracranial arterio-venous malformations. **Acta Neurochir (Wien) Suppl** **21**:195-209, 1974
43. Yang SY, Kim DG, Chung HT, Paek SH, Park JH, Han DH: Radiosurgery for large cerebral arteriovenous malformations. **Acta Neurochir (Wien)** **151**:113-124, 2009

TYPE OF EVIDENCE SUPPORTING THE RECOMMENDATIONS

Type I, II, and III evidence (Bandolier) exists in support of stereotactic radiosurgery for arteriovenous malformations.

POTENTIAL BENEFITS

- All the published studies have shown a significant response of stereotactic radiosurgery for arteriovenous malformations, including a high rate of AVM nidus obliteration, concomitant improvement in seizure control, headache resolution, and a satisfactory (low) rate of adverse radiation effect that might lead to additional neurological deficits.
- Potential successful outcomes include complete AVM obliteration, symptomatic relief, no new neurological deficits, no long-term complications and life-long prevention of bleeding risks.
- Literature has documented the cost savings benefit of stereotactic radiosurgery versus invasive surgical procedures and the lower risk potential of bleeding, anesthesia problems, infections and side effects which may result in transient or permanent disabilities from open surgery.

SUBGROUP(S) MOST LIKELY TO BENEFIT

Radiosurgery, a minimally invasive closed skull treatment strategy, may be especially suitable for:

- Patients in advanced age groups
- Patients with excessive medical co-morbidity risk factors for surgical excision
- Patients with malformations located in eloquent areas of the brain where open surgery would likely result in severe neurological deficits
- Patients with AVMs considered unsuitable for complete obliteration by endovascular embolization

POTENTIAL HARMS

Major adverse effects of radiosurgery are based on location, volume, dose, and flow, and these risks can be estimated based on published data and experience. Individual risks are related to the anatomical location of the AVM. Currently, the estimated adverse risk of permanent new neurological deficits related to radiation

in a large group of patients undergoing radiosurgery is 3–5%. Late delayed potential risks of radiosurgery should be assessed by MRI at five and ten years after obliteration is confirmed.

SUBGROUP(S) MOST LIKELY TO BE HARMED

- Patients with large volume AVMs who are treated with large doses in a single fraction, especially if the AVM is located in a deep brain area
- Patients with large AVMs in a deep brain area, in whom the risk of bleeding over their expected lifetimes is less than the risk of radiosurgery complications

CONTRAINDICATIONS

Patients with small volume (<3 cm³), lobar location malformations that can be easily removed or resected without permanent neurological deficits.

QUALIFYING STATEMENTS

This guideline is intended to provide the scientific foundation and initial framework for the person who has been diagnosed with an AVM. The assessment and recommendations provided in this guideline represent the best professional judgment of the working group at this time, based on research data and expertise currently available. The conclusions and recommendations will be regularly reassessed as new information becomes available.

This guideline is not intended as a substitute for professional medical advice and does not address specific procedures or conditions for any patient. Those consulting this guideline are to seek qualified consultation utilizing information specific to their medical situation. Further, IRSA does not warrant any instrument or equipment nor make any representations concerning its fitness for use in any particular instance nor any other warranties whatsoever.

DESCRIPTION OF THE IMPLEMENTATION STRATEGY

None

IMPLEMENTATION TOOLS

Clinical algorithm
Patient resources

RELATED MEASURES IN THE NATIONAL QUALITY MEASURES CLEARINGHOUSE™

None

IOM CARE NEED

Getting Better
Living with Illness

IOM DOMAIN

Effectiveness
Patient-centeredness

BIBLIOGRAPHIC SOURCE

International RadioSurgery Association (IRSA). Stereotactic radiosurgery for patients with intracranial arteriovenous malformations (AVM). Harrisburg (PA): International RadioSurgery Association (IRSA); 2009 March. 22 p. (Radiosurgery practice guideline report; no. 2-03). [84 references]

ADAPTATION

Not applicable: the guideline was not adapted from another source.

DATE RELEASED

2009 March

GUIDELINE DEVELOPER

IRSA – Professional Association

GUIDELINE DEVELOPER COMMENT

IRSA (International RadioSurgery Association) is an independent entity dedicated to promoting the development of scientifically relevant practice guidelines for stereotactic radiosurgery. IRSA is a professional organization that works to educate and provide support for physicians, hospitals, insurers and patients.

SOURCE(S) OF FUNDING

IRSA (International RadioSurgery Association)

GUIDELINE COMMITTEE

The IRSA Medical Advisory Board Guidelines Committee and representatives in the industry.

COMPOSITION OF GROUP THAT AUTHORED THE GUIDELINE

The radiosurgery guidelines group is comprised of neurosurgeons, radiation oncologists and physicists. Community representatives did not participate in the development of this guideline.

Committee Members: L. Dade Lunsford, M.D., Neurosurgeon, Chair; Douglas Kondziolka, M.D., Neurosurgeon; Ajay Niranjani, M.B.B.S., M.Ch., Neurosurgeon; Christer Lindquist, M.D., Neurosurgeon; Jay Loeffler, M.D., Radiation Oncologist; Michael McDermott, M.D., Neurosurgeon; Michael Sisti, M.D., Neurosurgeon; John C. Flickinger, M.D., Radiation Oncologist; Ann Maitz, M.S., Medical Physicist; Michael Horowitz, M.D., Neurosurgeon and Interventional Radiologist; Tonya K. Ledbetter, M.S., M.F.S., Editor; Rebecca L. Emerick, M.S., M.B.A., C.P.A., ex officio.

FINANCIAL DISCLOSURES/CONFLICTS OF INTEREST

IRSA makes every effort to avoid any actual or potential conflicts of interest that may arise as a result of a personal, professional, or business interest of a member of the radiosurgery guidelines group.

ENDORSER(S)

Not applicable

GUIDELINE STATUS

This is the updated release of the guideline.

GUIDELINE AVAILABILITY

Electronic copies: Available in Portable Document Format (PDF) from www.IRSA.org

AVAILABILITY OF COMPANION DOCUMENTS

None available

PATIENT RESOURCES

Patient resources are available online at www.IRSA.org

- Original Guideline ‘Intracranial arteriovenous malformations & stereotactic radiosurgery.’ Harrisburg (PA): IRSA. 2003. Print copies available from IRSA, 3002 N. Second St., Harrisburg, PA 17110.
- AVMs. *Brain Talk* 2003;8(2):1-8. Electronic copies available in Portable Document Format (PDF) from <http://irsa.org/publications.html>
- Neurosurgical radiosurgery. *Brain Talk* 2001;6(1):1-12. Electronic copies available in Portable Document Format (PDF) from <http://irsa.org/publications.html>
- Radiosurgery & radiation therapy overview. *Another Perspective* 1999;4(2):1-12. Electronic copies available in Portable Document Format (PDF) from <http://irsa.org/publications.html>

COPYRIGHT STATEMENT

Copyright IRSA 2009. This guideline is copyrighted by IRSA (International RadioSurgery Association) and may not be reproduced without the written permission of IRSA. IRSA reserves the right to revoke copyright authorization at any time without reason.